

Laparoscopic gastropexy for the treatment of gastric volvulus.

Gastropexia laparoscópica para o tratamento do volvo gástrico

LUCIANO ANDREY FERREIRA-BICALHO¹, MARCO ALÍPIO RIBEIRO JÚNIOR², PAULO ROBERTO DE AZEVEDO-BICALHO³ AND PAULO ROBERTO RODRIGUES-BICALHO⁴

SERVIÇO DE CIRURGIA GERAL DO HOSPITAL SÃO LUCAS DE GOVERNADOR VALADARES

SUMMARY

Context: Gastric volvulus is an acquired, life-threatening condition in which the stomach rotates upon itself.

Objective: To describe the application of laparoscopic gastropexy in the case of severe gastric volvulus presented by an elderly female. **Method:** A 69 year old woman presenting severe abdominal pain with, retching and the incapacity to vomit, small dysphagia and sensation of post-prandial fullness was admitted to Hospital São Lucas de Governador Valadares, Brazil. Following clinical examination, the patient was submitted to plain and contrast x-rays of the abdomen and chest, computed tomography of the abdomen and upper gastrointestinal endoscopy. Laparoscopic gastropexy was performed in which the diaphragmatic hernia was reduced, the hiatus sutured, and anti-adhesive polypropylene mesh applied for fixation of the stomach. **Results:** The clinical, radiological and imaging features were typical of gastric volvulus. Rotation of the stomach was successfully corrected by laparoscopy and the patient was discharged from hospital three days after surgery. One month later, the patient was totally asymptomatic with respect to the digestive tract.

Conclusions: An adult female patient suffering from acute gastric volvulus was successfully treated using a laparoscopic approach applied ten days after admission to hospital. Early diagnosis and the prompt surgical correction of such cases are crucial in reducing mortality in gastric volvulus.

Keywords: Gastric Volvulus, Abdominal Pain, Vomiting, Laparoscopic Gastropexy.

RESUMO

Contexto: Volvo gástrico é uma condição adquirida, com risco de vida, na qual o estômago sofre um deslocamento em torno de seu eixo. **Objetivo:** Relatar a aplicação de gastropexia laparoscópica numa paciente idosa, apresentando volvo gástrico grave. **Método:** Uma mulher de 69 anos de idade, apresentando dor abdominal severa, náusea e incapacidade de vomitar, pequena disfagia e sensação de plenitude pós-prandial foi admitida no Hospital São Lucas de Governador Valadares, Brasil. Após o exame clínico, foram realizadas radiografias do abdômen e peito (simples e de contraste), juntamente com tomografia de endoscopia superior. Após o diagnóstico, a paciente foi submetida à laparoscopia. A hérnia do diafragma foi reduzida junto com sutura hiatal, além da aplicação de uma tela de polipropileno anti-aderente para fixação do estômago. **Resultados:** As características clínicas, radiológicas e de imagem revelaram um volvulus gástrico típico. A rotação do estômago foi corrigida com sucesso através de laparoscopia e a paciente foi liberada do hospital após três dias da operação. Um mês após a cirurgia, a paciente encontrava-se totalmente assintomática no que diz respeito ao trato digestivo.

Conclusões: Uma paciente adulta, sofrendo de volvo gástrico agudo, foi tratada com sucesso através de procedimento laparoscópico realizado dez dias após a internação hospitalar. O diagnóstico precoce e a correção cirúrgica breve são essenciais para a redução da mortalidade em casos de volvo gástrico.

Unitermos: Volvulus Gástrico, Dor Abdominal, Vômitos, Gastropexia Laparoscópica.

1. Médico especialista em gastroenterologia e endoscopia digestiva. 2. Médico especialista em cirurgia geral e gastroenterologia. 3. Médico especialista em cirurgia geral. 4. Médico especialista em cirurgia geral, cirurgia do aparelho digestivo, endoscopia digestiva e mestre em ciências aplicadas à cirurgia e à oftalmologia. **Endereço para correspondência:** Dr. Paulo R. Rodrigues-Bicalho - Hospital São Lucas de Governador Valadares, 35010230, Governador Valadares, MG, Brazil. Phone: +55 33 3277-8272 / e-mail: gpbicalho1@uol.com.br. **Recebido em:** 24/11/2009. **Aprovado para publicação:** 30/03/2010.

INTRODUCTION

Gastric volvulus, derived from the Latin *volvere* - “to turn about”, refers to the twisting of the stomach leading to the partial or total obstruction of normal flow¹³. This clinical condition is relatively rare and may result from primary (e.g. organ not firmly attached or agenesis of gastric ligaments) or secondary (e.g. adhesions, hiatal hernia) aetiologies¹⁸.

The topographic classification of gastric volvulus described by LONGO¹⁰ involves five specific descriptors, namely, type [i.e. rotation around the longitudinal axis (organoaxial), the transversal axis (mesenteroaxial) or a combination of both⁸], extension, direction, aetiology and severity (Table 1). One-third of recorded cases of gastric volvulus are associated with diaphragmatic defects. Indeed, this pathology was first described in 1579 by a French physician named Ambroise Paré following examination of a patient who had developed a diaphragmatic hernia after having received a sword wound². More common predisposing factors are, however, diaphragmatic trauma or paralysis, neoplasia or gastric ulcers and extrinsic compression by abdominal mass¹.

The symptoms of gastric volvulus depend on the degree of rotation of the stomach, and are particularly intense when this exceeds 180°. The symptomatology of the disorder varies, therefore, from asymptomatic to extremely serious conditions that may impair gastric irrigation and disrupt the release of

stomach contents⁸. Acute gastric volvulus is characterised by sudden abdominal pain, accompanied by the Borchartd triad, i.e. epigastric distension, retching without vomiting, and difficulty (or failure) in passing a nasogastric tube. Patients presenting these conditions are predisposed to develop mucosal ischemia, necrosis and gastric perforation. Such cases usually have an inauspicious evolution and require emergency surgery^{6,9}. In contrast, chronic volvulus may be accompanied by the absence of symptoms or it may be oligosymptomatic characterised by abdominal discomfort and, generally, heart-burn^{6,11}.

Gastric volvulus can be diagnosed by plain x-ray of the abdomen or contrast x-ray of the upper gastrointestinal tract^{3,4}. Plain x-ray allows the detection fluid levels in the upper abdomen, which may be accompanied or not by hiatal or diaphragmatic hernia. In contrast x-ray, employed to confirm the degree of rotation, a small quantity of contrast may pass into the stomach and reveal accentuated gastric dilation together with the location and type of rotation. In addition, upper gastrointestinal endoscopy (*syn.* esophagogastroduodenoscopy; EGD), an alternative method employed in the diagnosis of gastric volvulus, enables the examiner to detect difficulties in the introduction of the tube into the twisted region of the stomach. Among the differential diagnostics are gastric atony, gastric dilation and pyloric obstruction⁵, but the radiographic and endoscopic features of such conditions are very different than those of gastric volvulus^{14,17}.

Table 1. Classification of gastric volvulus as proposed by LONGO¹⁰.

Criteria	Description
Type	
Organoaxial	The stomach rotates around a longitudinal axis that connects the cardia and the pylorus
Mesenteroaxial	The stomach rotates around a transversal axis that crosses the lesser and the greater curvature
Mixed	The stomach rotates around both axis
Extent	
Total	Complete rotation of the stomach (> 180°), usually associated with gastric dilation
Partial	Limited rotation of the stomach, usually involves the pylorus
Direction	
Anterior	Rotation in clockwise direction, colon lies in front of the stomach
Posterior	Rotation in anticlockwise direction, colon lies behind the stomach
Aetiology	
Primary	Idiopathic, abnormal laxity of the gastrosplenic, gastroduodenal, gastrophrenic or orgastrohepatic ligaments
Secondary	Usually associated with congenital or acquired pathologies that result in abnormal mobility of the stomach.
Severity	
Acute	Grave form; manifests itself as the sudden onset of abdominal pain
Intermittent	Irregular abdominal pain and abdominal fullness following meals
Chronic	Symptoms of non-specific nature; recurrent symptoms or asymptomatic

Correction of gastric volvulus involves operative intervention, a procedure first carried out successfully by Berg in 1896⁶. The present article describes a case of gastric volvulus in a 69 year old patient, and the successful correction of the condition using laparoscopic gastropexy. The propedeutics and evolution of the patient are discussed.

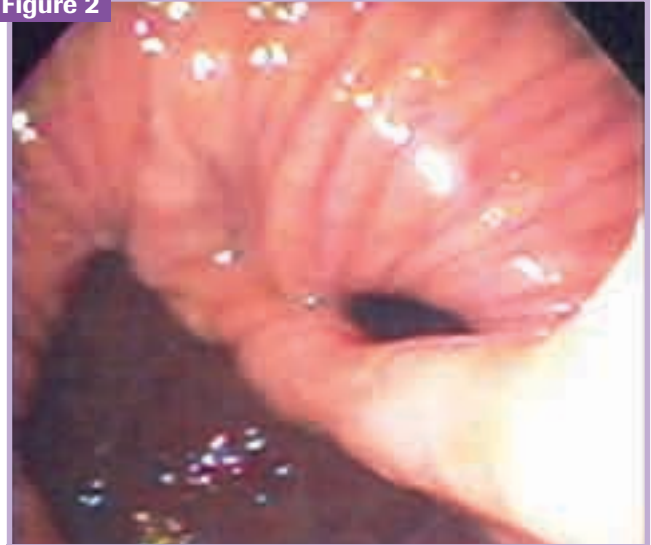CASE REPORT

A 69 year old female patient (dark skinned, married) from Tarumirim (State of Minas Gerais, Brazil) was admitted to São Lucas Hospital at 10:00 h on the 30th July 2007. On arrival the patient presented severe abdominal pain, uncontrollable vomiting, small dysphagia and post-prandial fullness sensation. The symptoms had commenced on the 26th July 2007, two days after which the patient had visited the out-patient depart of the hospital where she was medicated and sent home with advice to continue the treatment. Since the symptoms were not relieved by the therapy applied, the patient was interned at the hospital and maintained *nil per os*. Although the passage of a nasogastric tube was attempted in order to decompress the stomach, the patient did not allow its introduction.

Abdominal and chest x-rays showed air-fluid level in the right hemithorax. Since vomiting persisted and the stomach remained full, the patient was submitted to computed tomography (CT) of the abdomen, which revealed the almost complete displacement of the stomach to an intra-thoracic position (Figure 1). EGD indicated the presence of oesophageal moniliasis, intense erosive esophagitis and a massive rolling hiatal hernia. It was difficult to introduce

the endoscope into the antrum because of a mucosal fold that not disappeared with air insufflation, an outcome that was compatible with the rotation of the stomach along its axis and, thus, typical of gastric volvulus (Figure 2).

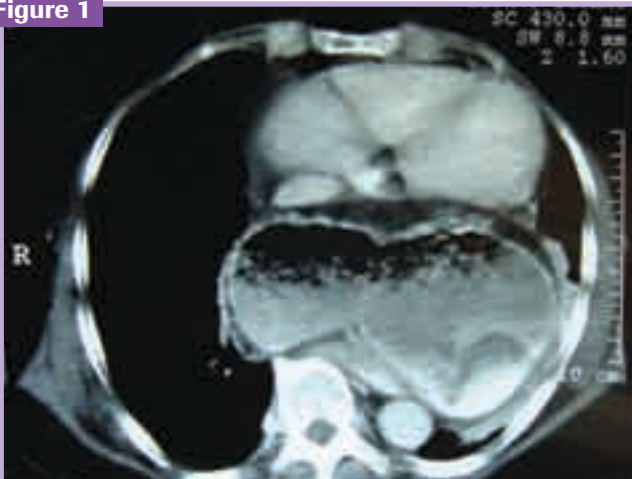
Figure 2



Endoscopic view of the stomach showing a mucosal fold that did not disappear with air insufflation. This facet is compatible with gastric volvulus

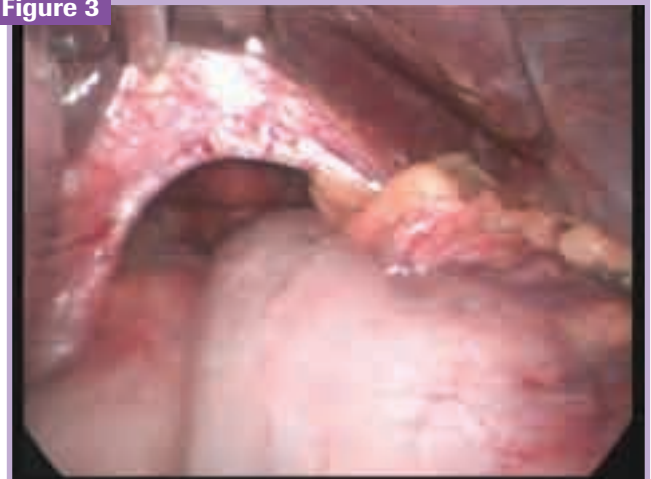Following diagnosis, the patient was submitted to laparoscopic gastropexy on 9th August 2007 with the aim of correcting the problem. The diaphragmatic hernia was reduced, the hiatus sutured, and anti-adhesive polypropylene mesh applied for fixation of the stomach (Figures 3 and 4).

Figure 1



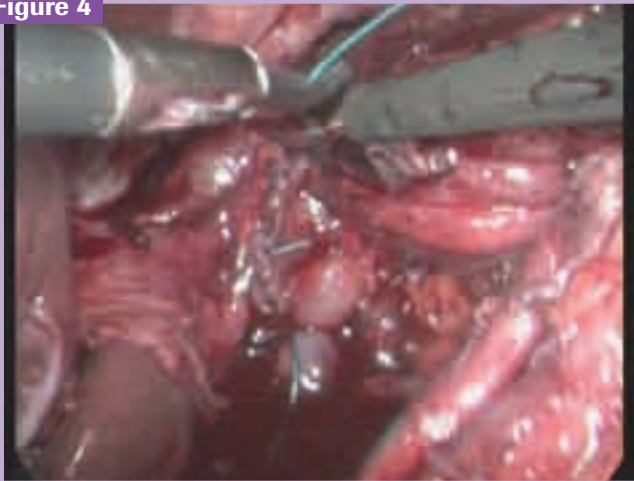
Computer tomography of the abdomen of the patient showing cardiac compression by the gastric hernia and rotation about its axis

Figure 3



Laparoscopic view showing extensive defects in the diaphragmatic defect

Figure 4



Laparoscopic view showing the hiatal orifice closed

The patient evolved well and there were no post-operative complications. Three days after surgery, the patient was discharged from the hospital and was medically followed-up as an out-patient. One month after surgery, the patient was totally asymptomatic with respect the digestive tract.

DISCUSSION

The stomach is stabilised by various important ligaments. The gastrocolic and gastrosplenic ligaments connect the greater curvature to the transverse colon and the splenic hilum, respectively, whilst the hepatogastric and gastroduodenal ligaments connect the lesser curvature to the liver and duodenum, respectively, together with the left gastric vasculature. The absence or failure of one of the connecting structures, the enhanced mobility of the viscera caused by a hiatal hernia, and the anomalous fixation of the gastric wall resulting from post-operative adhesions, all represent factors that predispose the individual to gastric volvulus¹¹. Additional predisposing factors for the disorder include enlargement of the adjoining organs (as in the case of distension of the angle of the spleen or transverse colon), the pathological elongation of the colon (dolichocolon), and the rotation of the sigmoid colon⁷.

In the present case study, admission examination of the patient revealed symptoms compatible with gastric volvulus including excruciating abdominal pain, retching, incapacity to vomit and the sensation of post-prandial fullness¹². Diagnosis was confirmed by plain x-ray, contrast x-ray and EGD. Subsequent CT of the abdomen clearly showed the almost complete intra-thoracic location of the stomach. It should be stressed that, according to FREITAS *et al.*⁸, it is essential to confirm the results of clinical examination with the imaging results in cases of gastro volvulus. Correction of the disorder

may be carried out either by open surgery or, more recently, by laparoscopy. Considering the successful results in anti-reflux surgeries that have been reported during the last decade, and the better acceptance of the procedure by patients, laparoscopy is now an advantageous alternative¹⁵. Whilst this technique offers many advantages, however, the procedure demands special training and associated problems cannot be overlooked. Moreover, the mortality rate for acute gastric volvulus can be up to 50%, owing mainly to strangulation of the oesophagus and stomach, and gastric ischemia¹⁶. Clearly earlier diagnosis and prompt surgical correction in such cases are crucial in diminishing morbi-mortality.

CONCLUSION

An adult female patient with acute gastric volvulus was examined by direct and indirect methods and the disorder was repaired successfully via a laparoscopic approach applied within 10 days after admission to hospital. It is clear that the earlier the diagnosis and treatment, the better the prognosis for the patient.

REFERENCES

1. Abalde A, Ramos CR, Trujillo IG, Collado JF, Ramirez F, Gonzalez V. Vólculo gástrico agudo de tipo mixto y localización intratorácica. *Rev Esp Enferm Dig.* 2007; 99:231-32.
2. Aoyama K, Tateishi K. Gastric volvulus in three children with asplenic syndrome. *J Pediatr Surg.* 1986;21:307-10.
3. Dagher M, Macmath TL, Seger DI. Mesenteroaxial gastric volvulus in children. *South Med J.* 1984;77:768-70.
4. Eckshauser ML, Ferron JP. The use of dual percutaneous endoscopic gastrostomy (DPEG) in the management of chronic intermittent gastric volvulus. *Gastrointest Endosc.* 1985;31:340-2.
5. Elidam J, Gimmon Z, Schwartz A. Pneumoperitoneum induced by pneumatosis cystoides intestinalis associated with volvulus of the stomach. *Am J Gastroenterol.* 1980;74:189-95.
6. Farag S, Fiallo V, Nash S, Navab F. Gastric perforation in a case of gastric volvulus. *Am J Gastroenterol.* 1996;91:1863-4.
7. Flynn P, Chapuis P, Pheils MT. Organoaxial volvulus of the stomach and volvulus sigmoid colon. *Med J Aust.* 1980;2:152-3.
8. Freitas CMG, Leite GMM, Resano MBS, Esberard-Filho C, Abrahão LJ. Volvo gástrico agudo associado a hérnia paraesofageana. *J Bras Med.* 1987;52:79-84.
9. Grendell HJ. Miscellaneous disorders of the stomach and small intestine. In: Grendell HJ, McQuaid R, Friedman LS (Eds.) *Current Diagnostic and Treatment in Gastroenterology*. Boston: Appleton and Lange; 1996, p. 363.
10. Longo A. Vólculo gástrico, consideraciones y caso clinico. *Arch Sci Med (Torino).* 1981;138:101-4.
11. Lopasso FP, Mello JB, Garrido AB, Rodrigues JGG, Raia A. Volvo gástrico: considerações sobre 22 casos. *Rev Ass Med Brasil.* 1981;27:121-6.
12. Lopes-Junior AG, Prospero MA. Valvuloplastia laparoscópica complicada com herniação gástrica paraesofágica aguda: relato de caso. *Gastroenterol Endosc Dig.* 2003;22:99-102.
13. Marchesini JB, Buffara-Junior VA, Marchesini JCD, Malafáia O. Vólculo gástrico: um estudo de 10 casos. *Rev Bras Cir.* 1994;84:9-11.
14. Pearson FG, Cooper JD, Ilves R. Massive hiatal hernia with incarceration. A report of 53 cases. *Ann Thorac Surg.* 1983;35:45-51.
15. Pinotti HW. *Tratado de Clínica Cirurgia do Aparelho Digestivo*, Vol. 1, 1st Edn. São Paulo: Livraria Atheneu Editora, 1994.
16. Teague WJ, Ackroyd R, Watson DI, Devitt PG. Changing patterns in the management of gastric volvulus over 14 years. *Br J Surg.* 2000;87:358-61.
17. Yousef AS, Di Lorenzo M, Yazbeck S, Ducharme JC. Volvulus gastrique chez l'enfant. *Chir Pediatr.* 1987;28:39-42.
18. Zinner M, Schwartz S, Ellis H. Diverticula, volvulus, superior mesenteric artery syndrome, and foreign bodies. In: Maingot R, Zinner MJ, Schwartz SI (Eds.) *Maingot's Abdominal Operations*, Vol 2, 10th Edn. Boston: Appleton and Lange; 1997, pp. 921-6.